Acute Local Radiation Injury (LRI) & Case Reviews

Carol J. Iddins, M.D.

REAC/TS Staff Physician

Radiation Emergency Assistance Center / Training Site

Oak Ridge Institute for Science and Education (ORISE)

U.S. Department of Energy (DOE)

24/7 Emergency Phone 865-576-1005

http://orise.orau.gov/reacts/

Terminal Objective

Understand diagnosis and management of Acute Local Radiation Injuries (LRI)

Enabling Objectives

- Describe the signs, symptoms and clinical phases of acute local radiation injury
- Identify the medical issues in acute LRI
- Discuss diagnosis and management of LRI

Approximate Surface Dose from Common Gamma Emitters

	rad/min per Ci	Sv/min per GBq
^{137}Cs	770	0.21
^{192}Ir	1200	0.32
^{226}Ra	1900	0.51
^{60}Co	3100	0.84

LRI Issues

- In many cases, one portion of the body receives a much higher dose than the rest of the body
- Severe injury to skin and underlying tissues may occur
- ARS may or may not be present
- Diagnosis is difficult; initial presentation is often misleading

LRI Issues

- Actual dose almost never known when patient is first seen
- Radiation dose estimates may be revised after the skin lesions run their course—usually over weeks
- Retrospective re-creation of incident and clinical dose thresholds will help with dose estimation

External Dose Thresholds Deterministic Effects for Skin

Dose [rads]	Sign	Timing
300	Epilation	begins around day 17
600	Erythema Distinguish from thermal burn	minutes to weeks, depending on dose
1,000–1,500	Dry desquamation	2-3 weeks post-exposure, depending upon dose
1,500-2,000	Moist desquamation	2-3 weeks post-exposure, depending upon dose
>2,500	Deep ulceration Radionecrosis	> 21 days

Radiation Histopathology of Skin

- Erythema - Arteriolar constriction with capillary dilation and edema, with extravasation of leukocytes and erythrocytes
- Dry Desquamation- Reflection of response of the germinal epidermal layer; diminished mitotic activity; cells of the basal layer swell; epidermis thins; desquamation of large macroscopic flakes of skin

Radiation Histopathology of Skin

- Moist Desquamation- Intracellular edema; vesicles coalesce to form bullae exterior to the basal layer; entire epidermis may slough, exposing the dermal surface, coated by fibrin

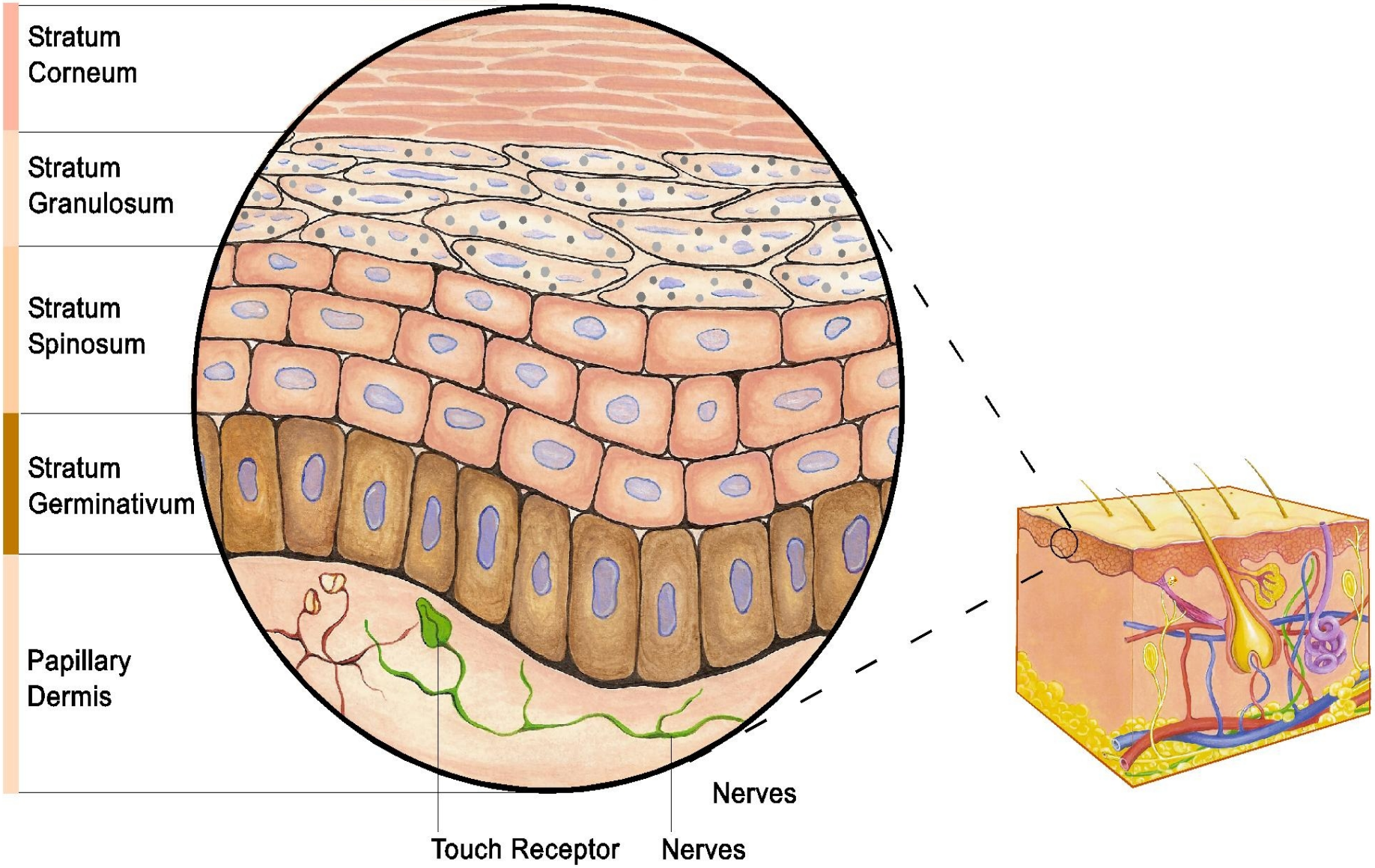
Stratum Corneum
Stratum Granulosum
Stratum Spinosum
Stratum Germinativum
Papillary Dermis
Nerves
Touch Receptor
Nerves

© REACTS 2010

Cellular Responses to Injury

- Ranges from cell damage / repair to **necrosis**
- Induces **inflammatory response**
- Induces reactive oxygen species (**ROS**) and reactive nitrogen species (**RNS**)
- Induces direct / indirect **damage to DNA**
- Induces **apoptosis**

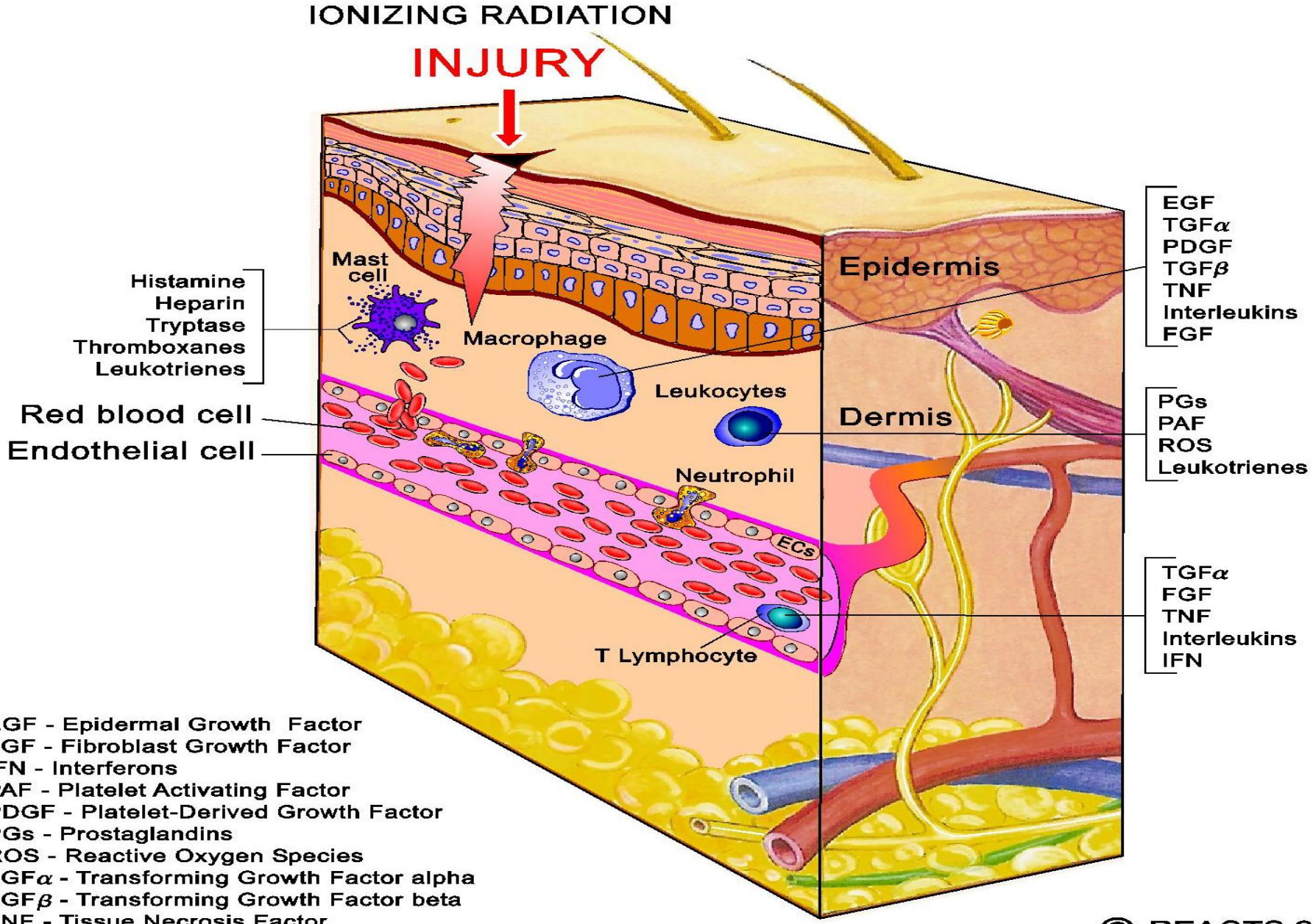

EGF - Epidermal Growth Factor
FGF - Fibroblast Growth Factor
IFN - Interferons
PAF - Platelet Activating Factor
PDGF - Platelet-Derived Growth Factor
PGs - Prostaglandins
ROS - Reactive Oxygen Species
TGFα - Transforming Growth Factor alpha
TGFβ - Transforming Growth Factor beta
TNF - Tissue Necrosis Factor

© REACTS 2010

Effects on the Vascular Endothelium

- Endothelial cells swell, pull up and/or detach from the basement membrane
- Edema occurs as leaks in denuded areas of microvasculature allow extravasation of fluids and cells
- Platelets fill in areas of denuded basement membrane and microthrombi form

Inflammatory Vascular Changes

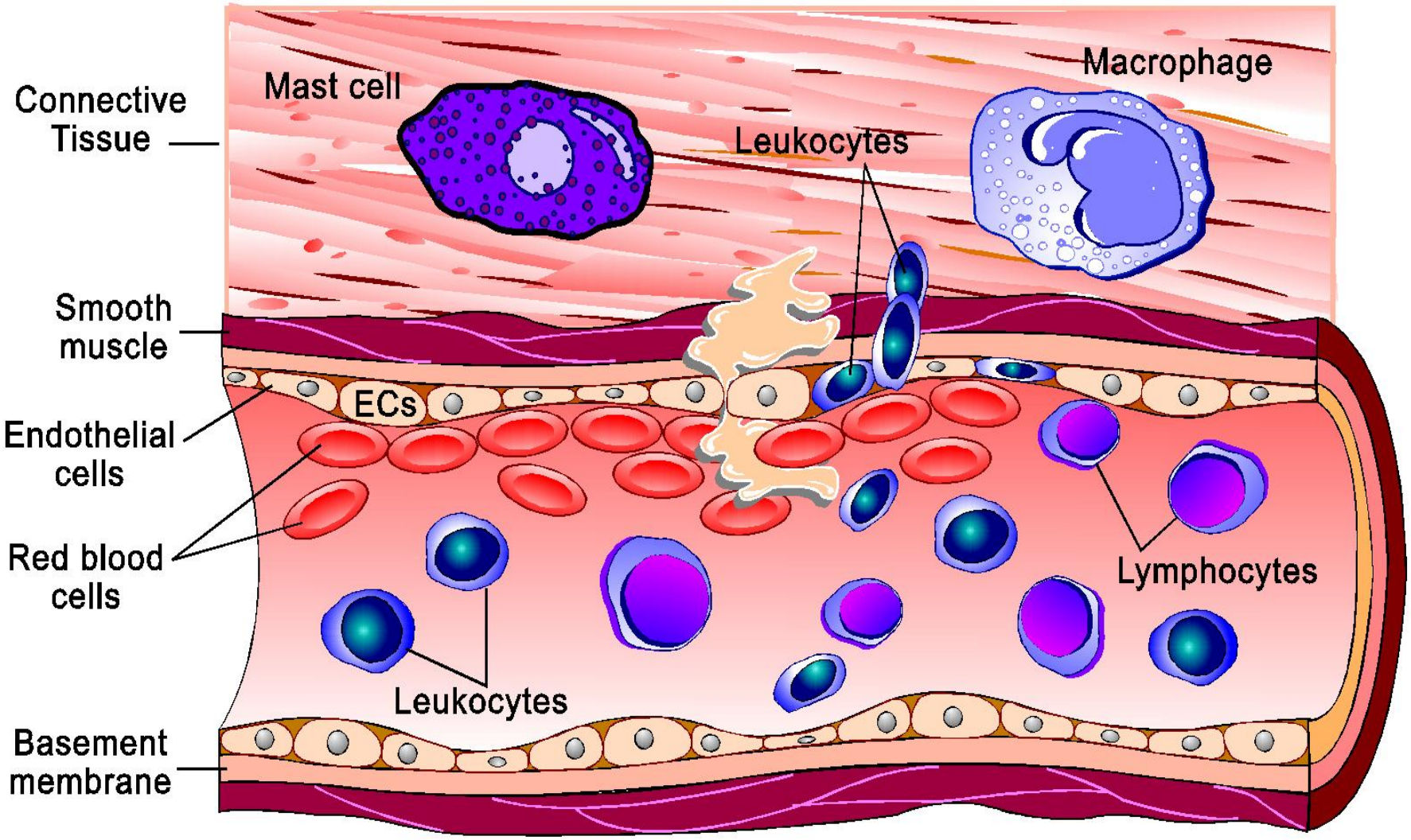

© REACTS 2010

Clinical Course

Irradiation Occurs

Prodrome

0 - 48 hours

- Transient erythema
- Migratory paresthesias
- Conjunctivitis
- Burning
- Pruritis

Clinical Course

Irradiation Occurs

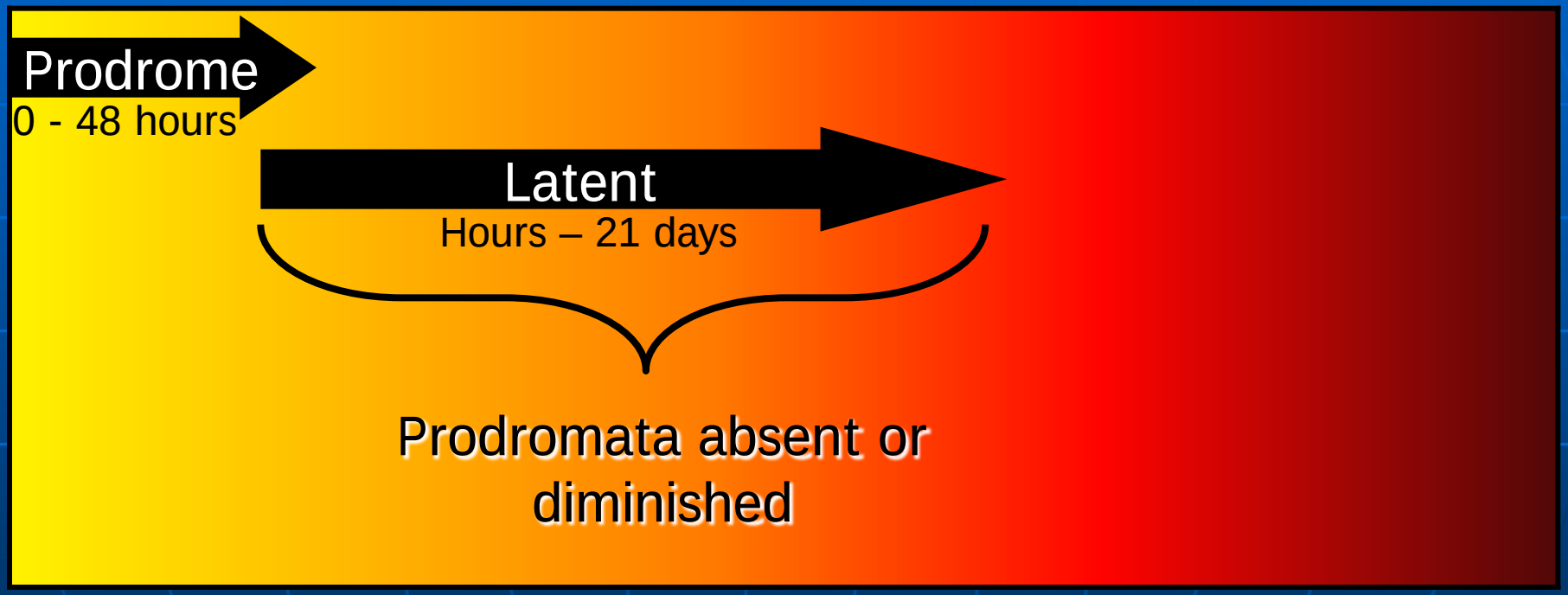

Clinical Course

Irradiation Occurs

Prodrome

0 - 48 hours

Latent

Hours – 21 days

Manifest Illness

Hours – 30 days

- Erythema
- Bronzing
- Blistering
- Desquamation
- Necrosis above 2,500 rads (25 Gy)
- Vascular and cutaneous damage
- Poor wound healing
- Pain
- Infections

Repair Process in Skin

- The epidermis is renewed by the proliferation of the epithelium at the edges of the denuded areas and from islands of surviving cells in the damaged zone
- The epidermis is also renewed from the epithelium of the hair follicles

Repair Process in Skin

- Effectiveness of repair is determined by:
  - Severity or injury to epidermal progenitor or stem cells
  - Adequacy of the microvasculature
  - Structural support of damaged dermis
  - Avoidance of infection and trauma

Diagnosis/Evaluation

- Incident history / re-creation
- Medical history: symptom onset and duration
- Physical examination: signs
- Determine local injury alone or with whole body exposure

Diagnosis/Evaluation

- Laboratory tests- CBC, amylase, C Reactive Protein, electron spin resonance
- Imaging – MRI (with angiography), thermography, ultrasound, blood pooling nuclear studies, other radiographic studies as indicated
- Serial digital color photographs – with blue background and measurement device

Evaluation and Diagnosis

- Ophthalmology consult – baseline slit lamp exam
- Cataract Dose threshold – Newer data indicates may be as low as 0.1 Gy
- 4000 rads/40 Gy – approximately 100% with cataracts
- Latency from 2 months – 35 years

LRI- Management

- Protect area
- Antihistamines
- Steroids/NSAIDS
- Pentoxyfylline with Vitamin E
- Infection prophylaxis and treatment
- Hyperbaric oxygen therapy (HBOT)

LRI- Management

- Ensure nutritional requirements
- Pain control
- Consultation - plastic surgery/burn surgery, dermatology, radiation oncology, surgical oncology, and possibly psychiatry
- Consider newer techniques in wound management

Other Techniques in Wound Management

- Topical Oxygen Therapy
  - http://www.topicaloxygen.com/
- Artificial skin (bi-layered) – epidermal/dermal constructs
- Bioengineered skin
  - Apligraf®
- Human skin allograft

Other Techniques in Wound Management

- Antioxidants, aloe vera, topical linoleic acid
- Transforming growth factor beta – 1 (TGF β-1) and TGF β-1 inhibitors
- Topical Granulocyte-Monocyte colony stimulating factor (GM-CSF)
- Mesenchymal stem cell therapy

Problems in Management

- Wounds evolve slowly with delayed healing
- Healed epidermis is fragile - easily traumatized with common recurrence of lesions
- Patient may be immunocompromised

Problems in Management

- Dose estimation is always imprecise
- Combined injury will always worsen prognosis
- Lesions can be intensely painful
- Long term disability

Patient D

- 56 YO male scuba diver; Smoked 3 ppd x 20 y. Strong hx CVD.
- Hx MI x 3; MI #4 en route to US from Thailand. Emergency landing in Taiwan.
- Fluoroscopy and stent placement in Taiwan. Under fluoroscope for as much as 5 h at 1-10 R/min skin dose. Total dose to back 40-50+ Gy.

Case Review

A Radiological Incident: Yanango Peru

February 1999

Location

- Yanango, Peru
- 42 megawatt Hydroelectric plant
- Located 300 km east of Lima,Peru

Events

- Welders repaired a fracture in a 2-meter pipe
- After repairs, a radiographic inspection was ordered to confirm the repair prior to hydrostatic testing



Device

^{192}Ir radiography device with a 1.37 TBq (37 Ci) source

Dose Rates

For a 30 Ci ^{192}Ir radiography source (as an example)

Distance [cm]	***Dose Rate [rad/min] or [cGy/min]***
Surface	36,000
1	2,400
2	600
3	267
4	150
5	96

Medical Facility

National Institute of Neoplastic Diseases (INEN)

Arrival in Lima 20 hours post exposure

Medical Situation

- 37 year old male with ~6 hour exposure
- Initial symptoms of nausea / vomiting and one episode of diarrhea
- Erythema on upper posterior thigh
- T_X - IV fluids, 500mg Cipro bid, 8mg dexamethasone tid, Naprosyn-like pain meds

Day 2 and Day 5

- 22 February
  - Blistering
  - Vesicular lesion with inflammatory halo
- 25 February
  - Clindamycin 300 mg 3x/day
  - Cipro increased to 750 mg/day

Day 6

CT Scan shows magnitude of edema

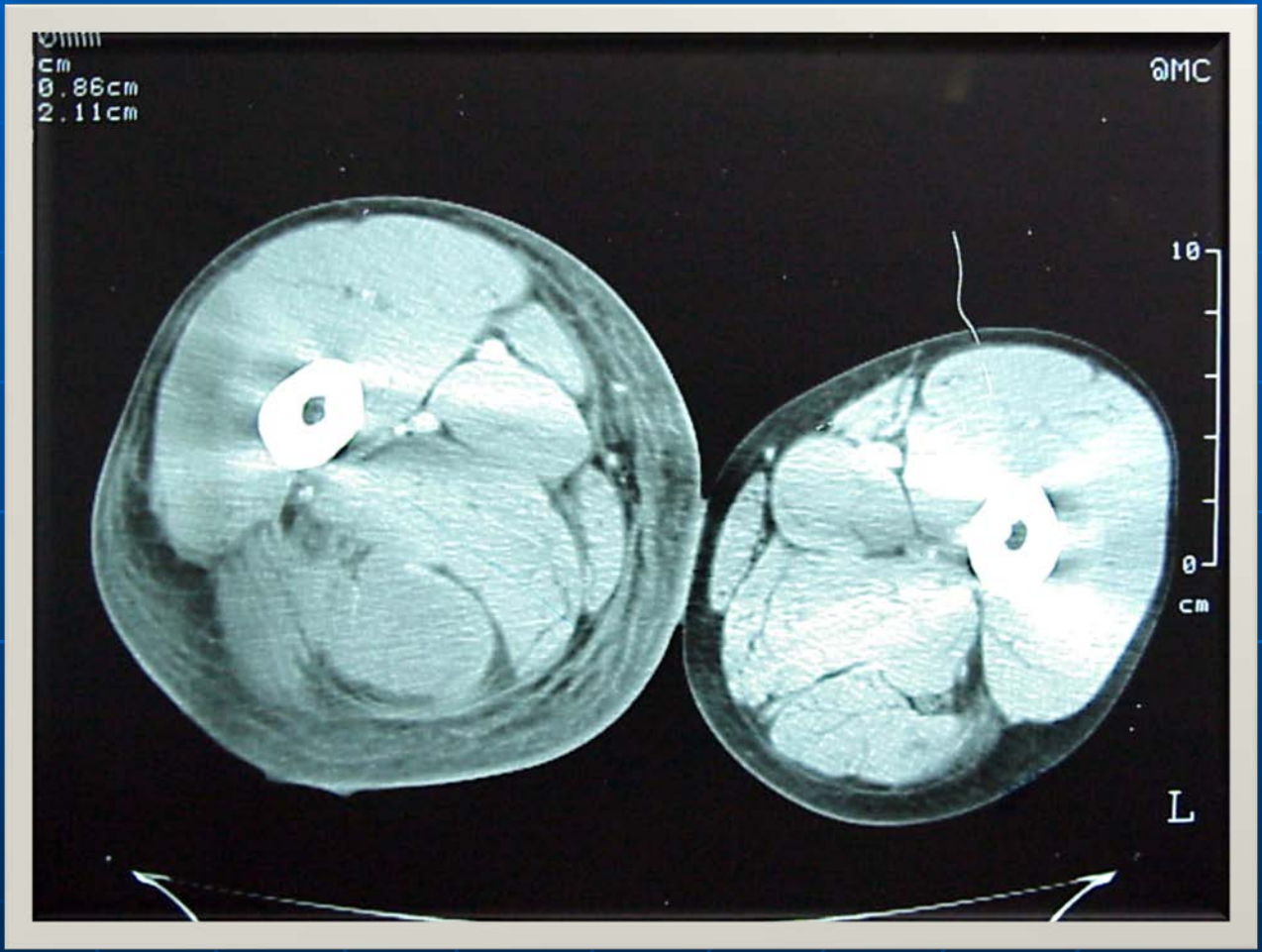

Lymphocyte Kinetics

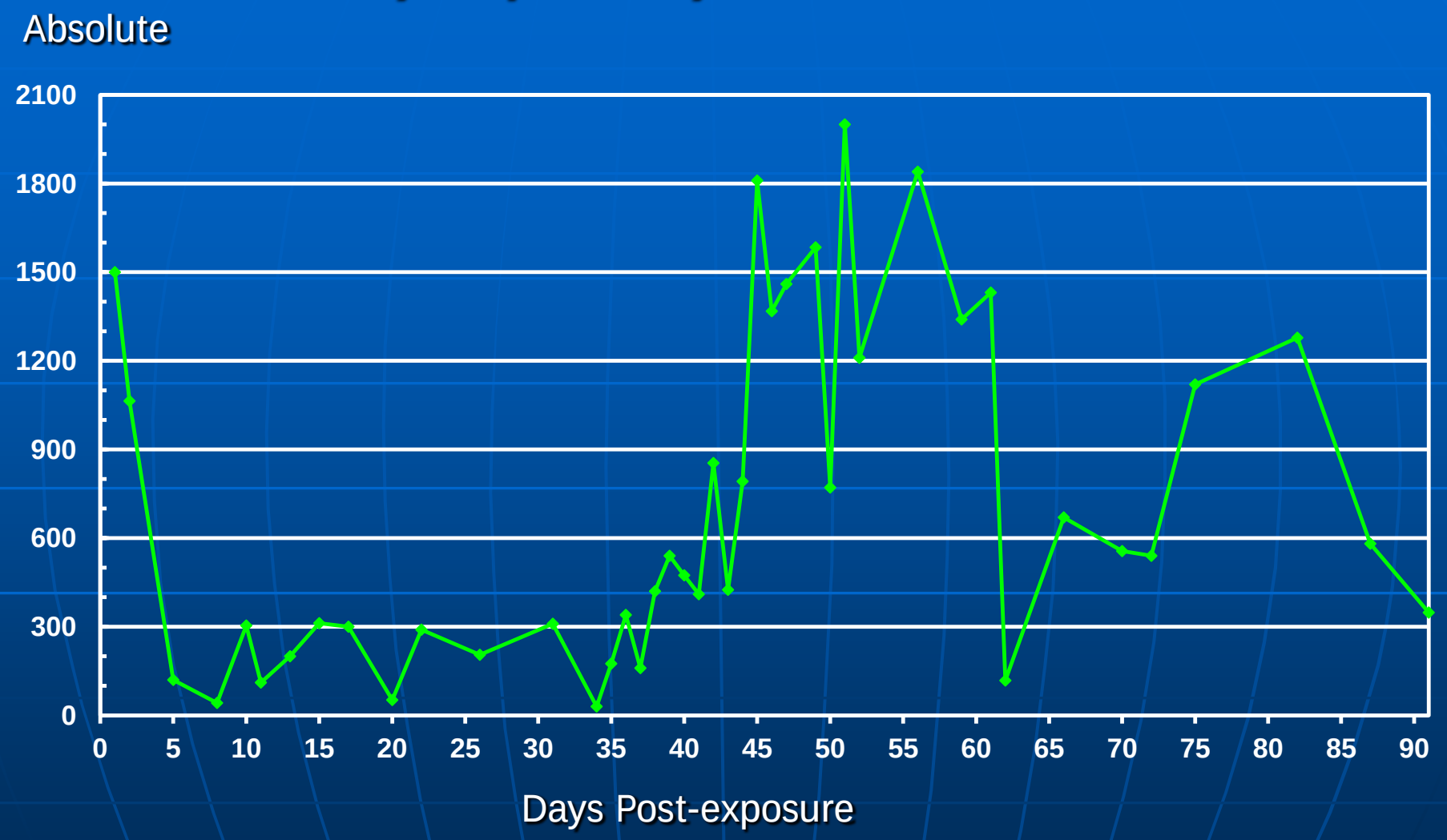

Day 10 and Day 15

- 1 March
  - Extended superficial erosion
- 6 March
  - Genital Herpes Eruption
  - Zinnet 500 mg 3x/day
  - Acyclovir 3x/day
  - Cipro stopped

Day 24

- 15 March
  - Pigment changes
  - Patient complains of numbness on lateral right thigh with hyper-sensitivity on medial side

Day 28

- 19 March
  - IAEA experts arrive and jointly review case with Peruvian doctors

Days 28, 32 and 39

- 19 March
  - Ulcerative lesion 2 cm deep continues to expand
- 23 March
  - Increasingly painful
  - Morphine infusion started
  - Radiation-induced sciatic neuropathy
- 30 March
  - First febrile episode

Late March

- Late March
  - More resource intensive
  - Nursing care and medical procedures are very time consuming
  - Lesions now appearing on right hand

Return from France to Peru

- Oct 1999
  - Very depressed with chronic pain
  - Ulcerated perineum continues to extend
  - Transferred to ICU in his hometown

November 1999

- Nov 1999
  - Ischial bone exposed
  - Urethral necrosis

Yanango Dose Estimates (Gy)

- Ranges from French, Peruvians, and REAC/TS estimates*
  - Skin 9,966 – 11,752
  - Sciatic Nerve 25 – 35
  - Femur 80-188
  - Bladder 16 - 21

*The Medical Basis for Radiation-Accident Preparedness. Proceedings of 4th International REAC/TS Conference, March 2001, pp. 267-281.

Wife: March 1999

- Mar 1999
  - Wife appears with moist desquamation in sacral region

Local Radiation Injury Issues

- There can be tremendous uncertainties associated with physical dose estimates and observed biological effects
- With evidence of bone marrow suppression, cytokines should be given as soon as possible
- If surgical intervention is indicated, it may need to be done within 24 – 48 hrs, before the patient becomes immunocompromised

Local Radiation Injury Issues

- Time and resource intensive
- There can be long-term pain control issues
- May be permanent disfigurement and / or disability
- Psychosocial well-being of the patient should be constantly addressed in the long-term healthcare plan

What We Have Learned

- Signs, symptoms, and clinical phases of acute local radiation injury (LRI)
- Medical issues in LRI
- Diagnosis and management of LRI

Questions?