Acute Local Radiation Injury (LRI)
&
Case Reviews

Doran M. Christensen DO
Associate Director/Staff Physician
Radiation Emergency Assistance Center/Training Site
Oak Ridge Institute for Science & Education (ORISE)
24/7 Emergency Phone: 865-576-1005

Terminal Objective

Understand diagnosis and management of acute Local Radiation Injuries (LRI)

Enabling Objectives

- Describe the signs, symptoms and clinical phases of acute local radiation injury (LRI)
- Identify medical issues in acute local radiation injury
- Discuss diagnosis and management of LRI

Approximate Surface Dose from Common Gamma Emitters

	rad/min per Ci	Sv/min per GBq
^{137}Cs	770	0.21
^{192}Ir	1200	0.32
^{226}Ra	1900	0.51
^{60}Co	3100	0.84

LRI Issues

- In many cases, one portion of the body receives a much higher dose than the rest of the body
- Diagnosis is difficult - initial presentation is often misleading
- Actual dose is rarely known when patient is first seen
- Severe injury to skin and underlying tissues may occur

LRI Issues (continued)

- ARS may or may not be present
- Radiation dose estimates may be revised after the skin lesions run their course - usually over weeks
- Retrospective mock-up of an incident may be very helpful

Diagnosis

- History of the incident and mock-up
- Medical history – symptom onset and duration
- Physical examination - signs
- Verify local versus whole body exposure

LRI - Evaluation and Diagnosis

- Laboratory tests - CBC, amylase, ESR, CRP
- Special testing - *e.g.,* MRA, blood pooling nuclear studies, thermography, ultrasound
- Physical examination
- Radiographic studies as indicated
- Slit lamp ophthalmoscopy for baseline - radiation-induced cataracts
- Serial color photos – during initial assessment, get baseline photos with blue background & measurement device

Radiation Cataract Evaluation & Diagnosis

- Evaluation by slit lamp ophthalmoscopy
- Doses - time required to induce cataracts
  - Threshold - 200 rads (2 Gy), higher with fractionated doses
  - 4000 rads (40 Gy): ~100% with cataracts
  - Latency period: 2 mo – 35 yrs

Dose		*Latency Period*
rads	*Gy*	
250 - 650	2.5 - 6.5	+/- 8 yrs
650 - 1150	6.5 - 11.5	+/- 4 yrs
>1150	>11.5	Increased dose, decreased latency period

Clinical Course: Skin Effects

Irradiation Occurs

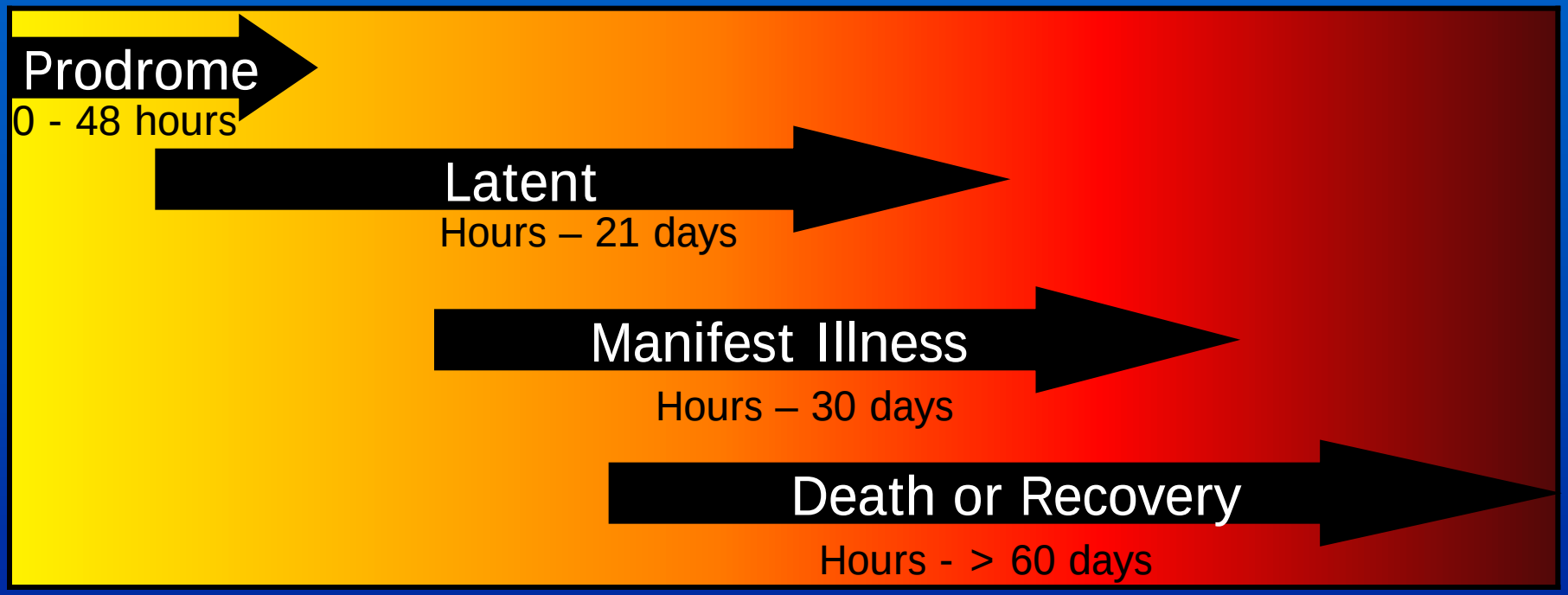

Clinical Course: Skin Effects

Irradiation Occurs

Prodrome
0 - 48 hours

Transient erythema

Migratory paresthesias

Conjunctivitis

Immediate effect of cell membrane damage

Release of vasoactive and other amines that initiate inflammatory response

Mediated neurologically by the parasympathetic system

External Dose Thresholds Deterministic Effects for Skin

Dose [rads]	Sign	Timing
300	Epilation	begins around day 17
600	Erythema Distinguish from thermal burn	minutes to weeks, depending on dose
1,000 – 1,500	Dry desquamation	2-3 weeks post-exposure, depending upon dose
2,000 – 5,000	Wet desquamation	2-3 weeks post-exposure, depending upon dose
>5,000	Deep ulceration Radionecrosis	

Clinical Course: Skin Effects

Irradiation Occurs

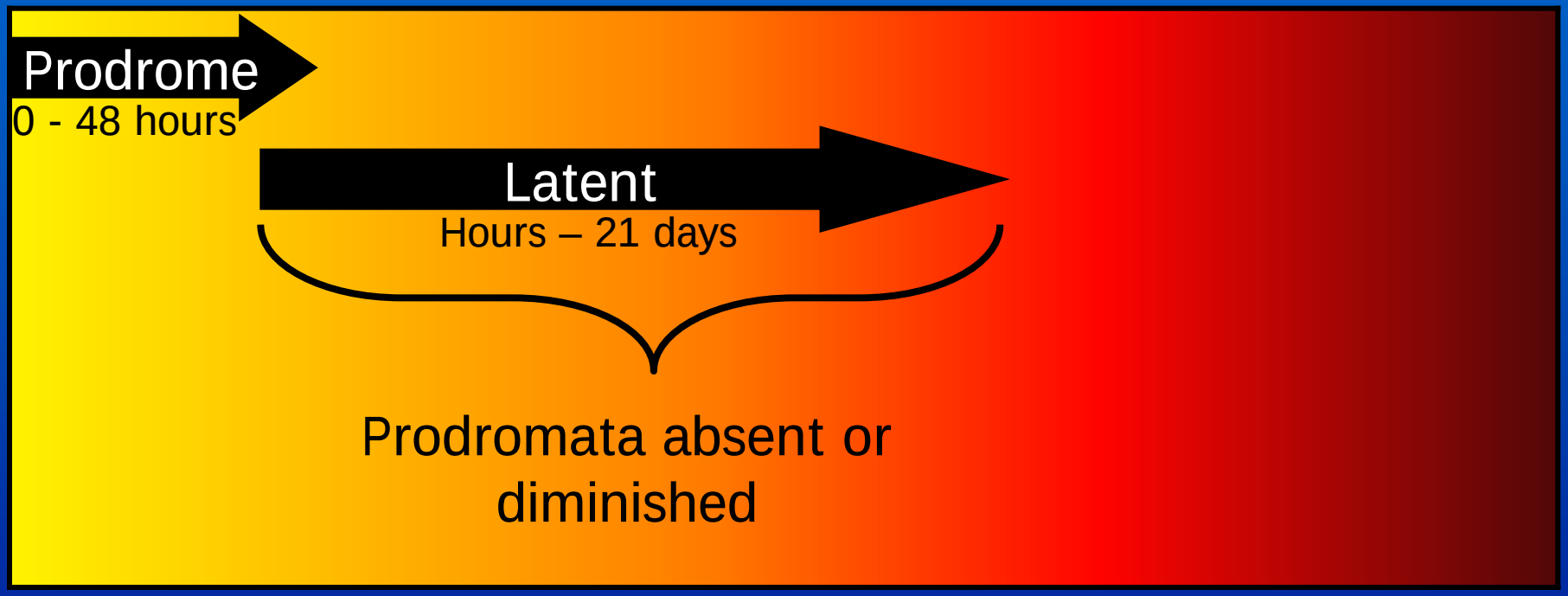

Clinical Course: Skin Effects

Irradiation Occurs

Prodrome
0 - 48 hours

Latent
Hours – 21 days

Manifest Illness
Hours – 30 days

Erythema	Vascular and cutaneous damage
Bronzing	Poor wound healing
Blistering	Pain
Desquamation	Infections

Necrosis above 5000 rads (50 Gy)

LRI - Management

- Protect area
- Avoid nicotine and other vasoconstrictors
- Hematorheologics – *e.g.*, pentoxyfylline
- Vitamin E (alpha-tocophorol succinate)
- Infection prophylaxis and treatment
- Ensure nutritional requirements
- Control pain
- Consult with experts – plastic surgery, burn surgery, vascular surgery, dermatology, radiation oncology
- Consider newer techniques in wound management

LRI: Problems in Management

- Wounds evolve slowly
- Healing is quite prolonged
- Lesions can be intensely painful
- Dosimetry is frequently imprecise
- Healed epidermis is fragile - easily traumatized with common recurrence of lesions
- Combined injury will worsen prognosis

~Day 14
1
2
3
4
5
SUBJECT :
DESCRIPTION :
9/12/2000

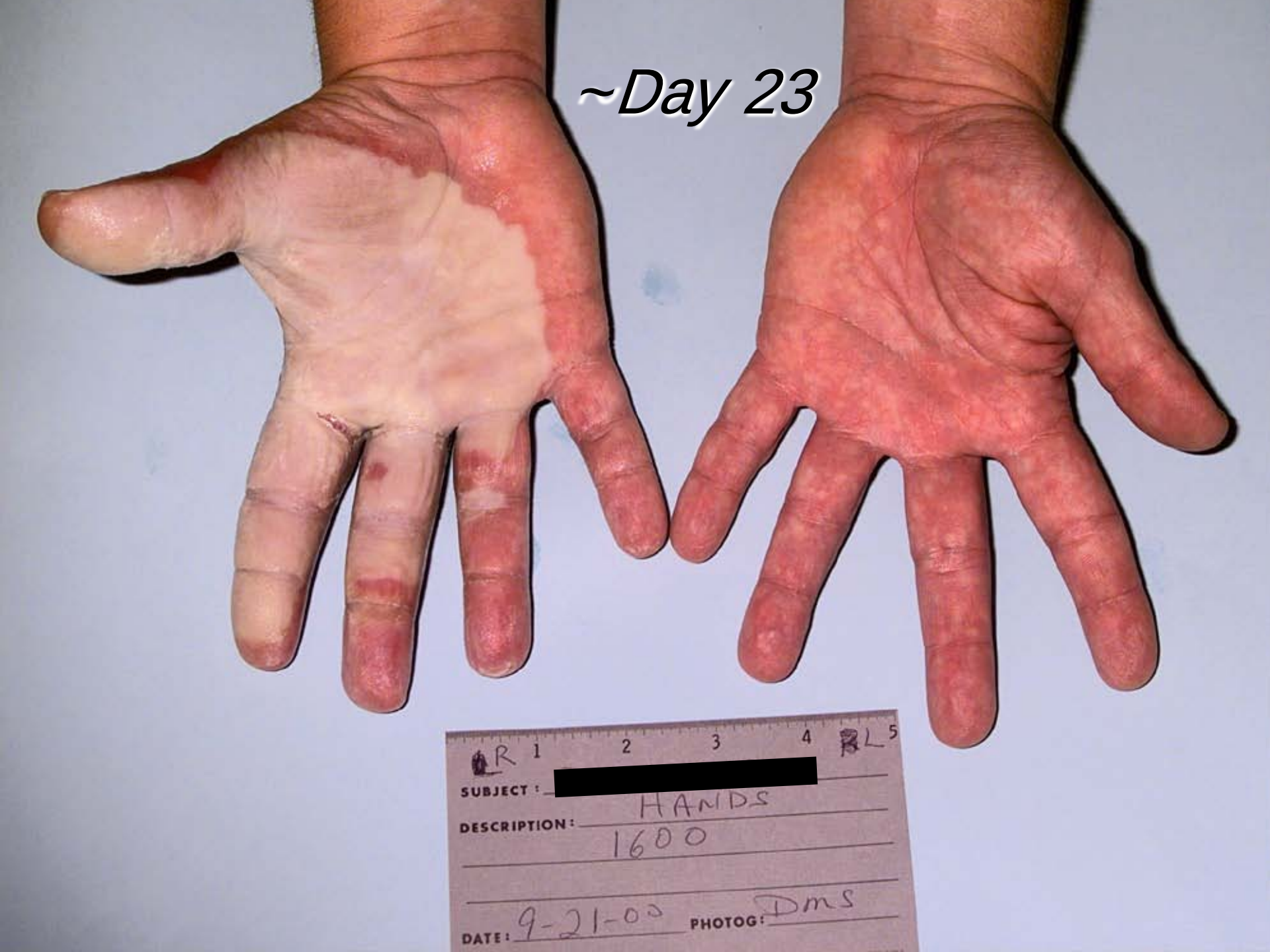
~Day 23
R 1 2 3 4 L 5
SUBJECT: [redacted]
DESCRIPTION: HANDS
1600
DATE: 9-21-00
PHOTOG: DMS

~Day 37
R
1
2
3
4
L
5
SUBJECT:
[redacted]
DESCRIPTION:
DATE: 10/3/00
PHOTOG:
154966-23

LRI - Day 9

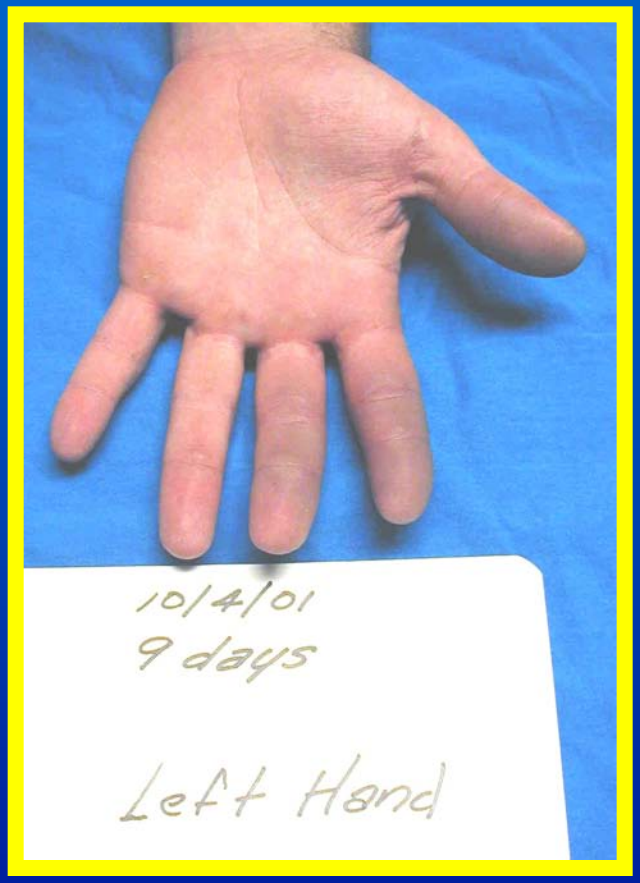

LRI - Day 13

LRI - Day 19

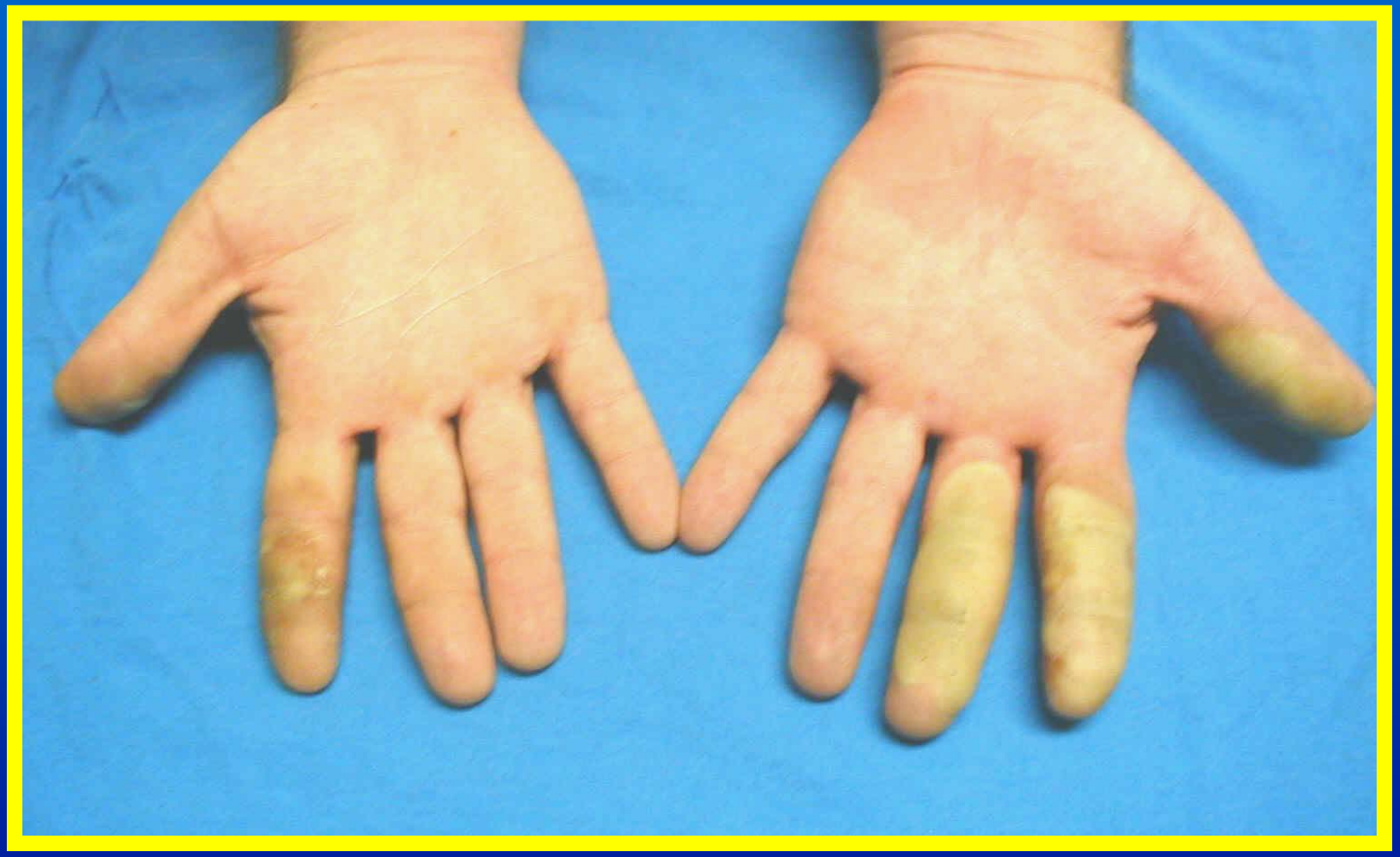

LRI - Day 25

LRI - Day 45

LRI - Day 108

Case Review

A Radiological Incident
Yanango Peru
February 1999

Location

Yanango, 42 megawatt hydroelectric plant, located 300 km east of Lima, Peru.

Events

- Welders repaired a fracture in a 2-meter pipe
- After repairs, a radiographic inspection was ordered to confirm the repair prior to hydrostatic testing

Device

^{192}Ir industrial radiography “camera” with a 1.37 TBq (37 Ci) source



Accident Chronology – 20 February 1999

1130 hrs - Radiographers arrive at work site to find repairs not finished. Radiography camera left at site, unsupervised with source locked inside the camera. Welders had left for lunch.

1400 hrs - Welders return from lunch to complete repairs.

1600 hrs - Welder finds unshielded source outside of camera and places source in pocket.

2100 hrs - Develops pain in back of right thigh & leaves work to go home at 2200 hrs.

Accident Chronology – 21 February 1999

2200 hrs - Radiographer performs pipe x-ray only to discover non-exposed film on development

0000 hrs - Survey instruments confirm missing source and company officials notified

0100 hrs - Emergency search personnel arrive at the welder's house and discover the source

0200 hrs - Source recovered - welder and family taken to Lima for medical attention

Dose Rates

For a 30 Ci ^{192}Ir radiography source

Distance [cm]	Dose Rate [rad/min] or [cGy/min]
Surface	36,000
1	2,400
2	600
3	267
4	150
5	96

Medical

National Institute of Neoplastic Diseases (INEN)

Arrival in Lima 20 hours post exposure

Medical

- 37 year old male with ~6 hour exposure.
- Initial symptoms of nausea / vomiting and one episode of diarrhea.
- Erythema on upper posterior thigh
- Admission.
- T_x - IV fluids, 500mg Cipro bid, 8mg dexamethasone tid, Naprosyn-like pain meds

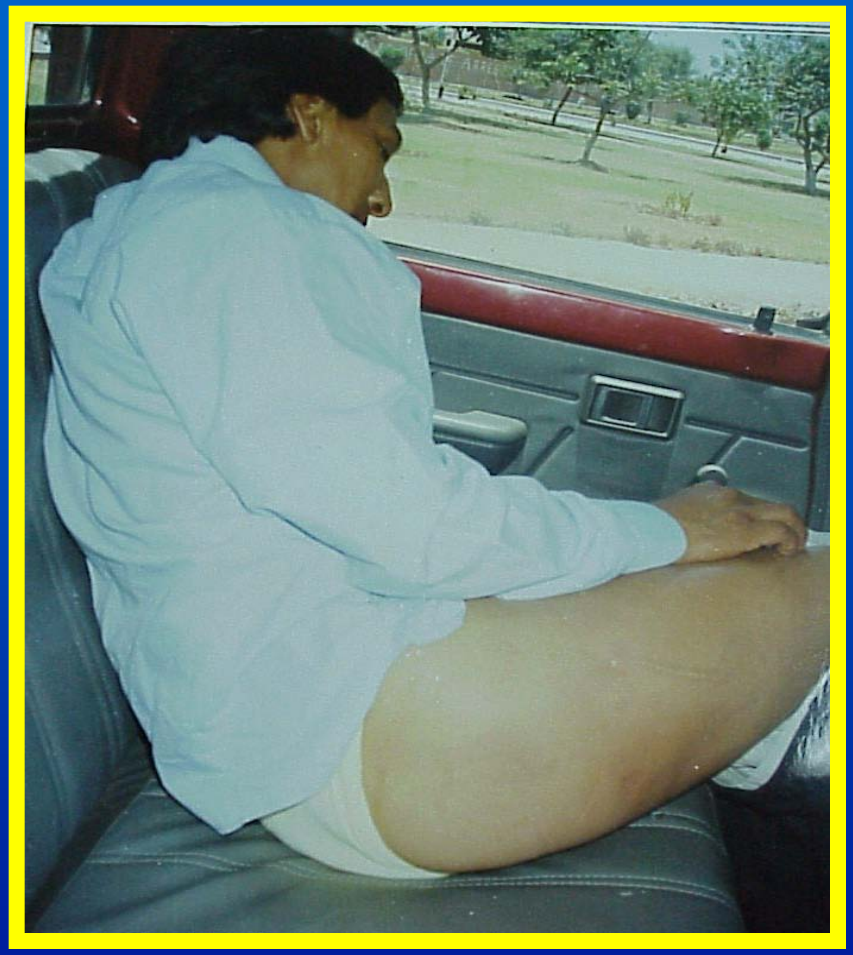

D+2 (Feb 22, 1999)

Blistering, vesicular lesion with inflammatory halo

D+5 (Feb 25, 1999)

Clindamycin 300mg tid started & Cipro ↑ 750mg bid

D+6. CT Scan demonstrates magnitude of edema
26 February 1999

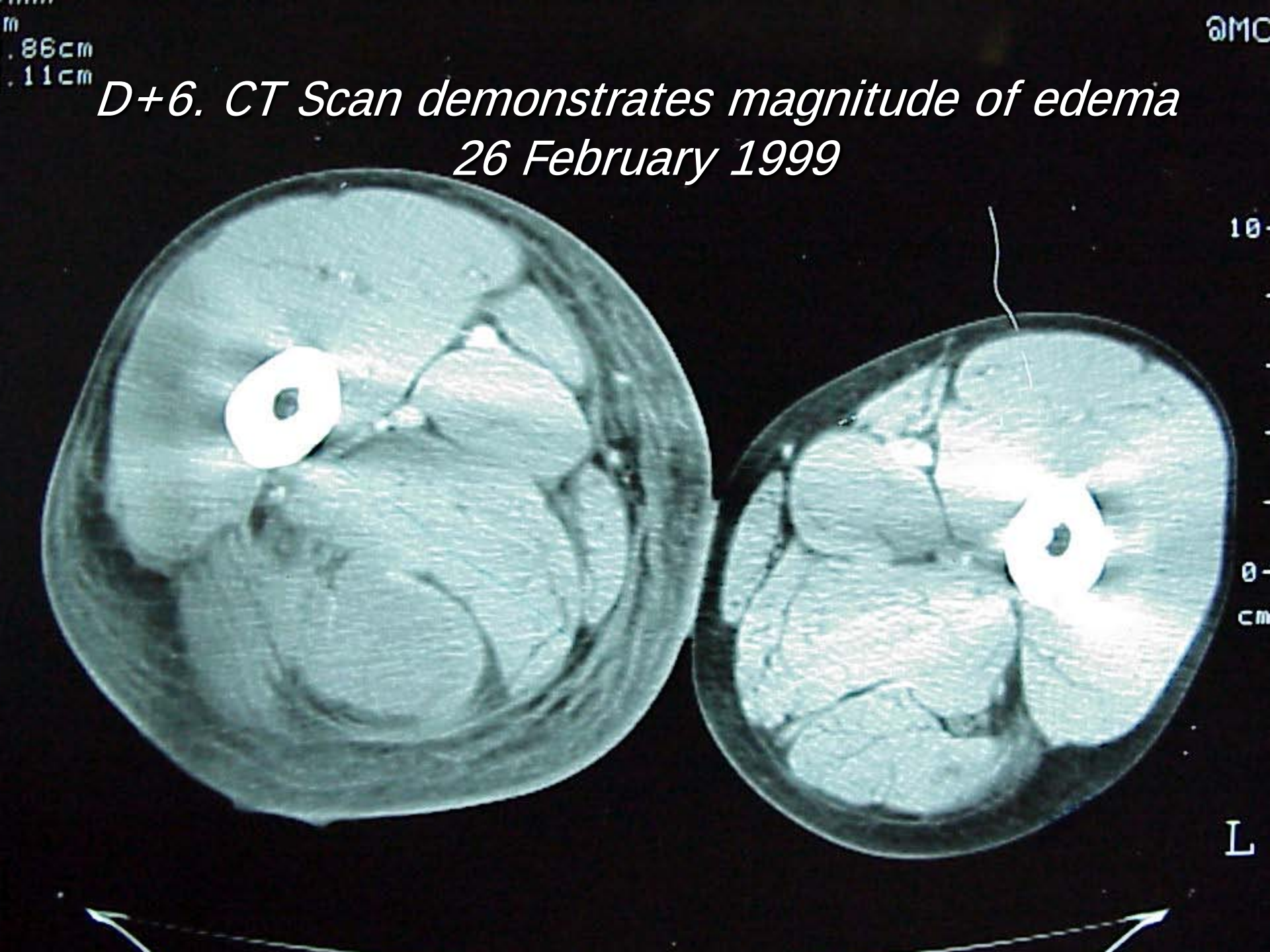

Absorbed doses in Gy
Normalized to 30 Gy at the rim of the lesion (radius = 5 cm)

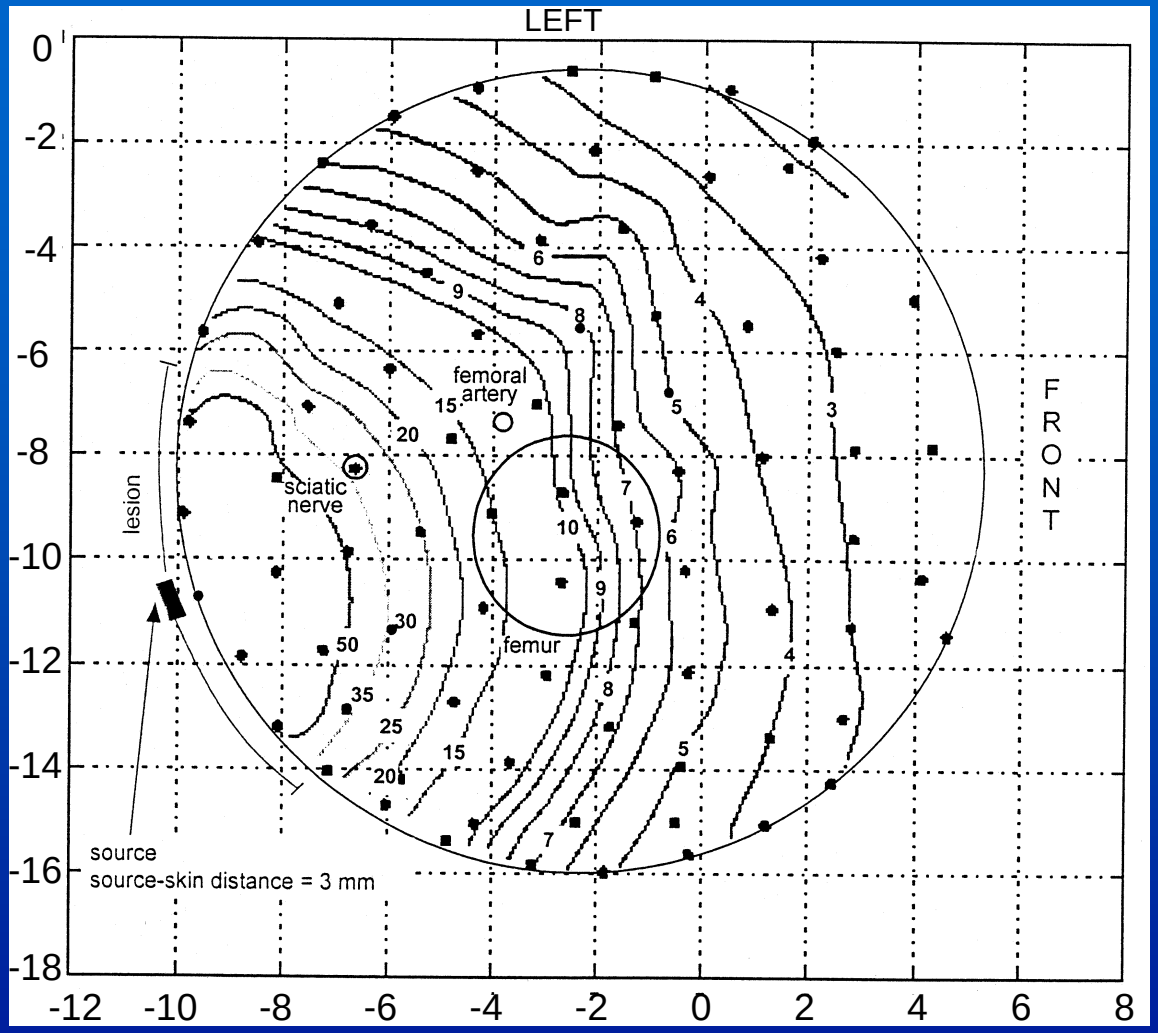

Absorbed dose distribution for horizontal cross-section at source level with source-skin distance of 3 mm

Lymphocyte Kinetics

Absolute Lymphocyte Count

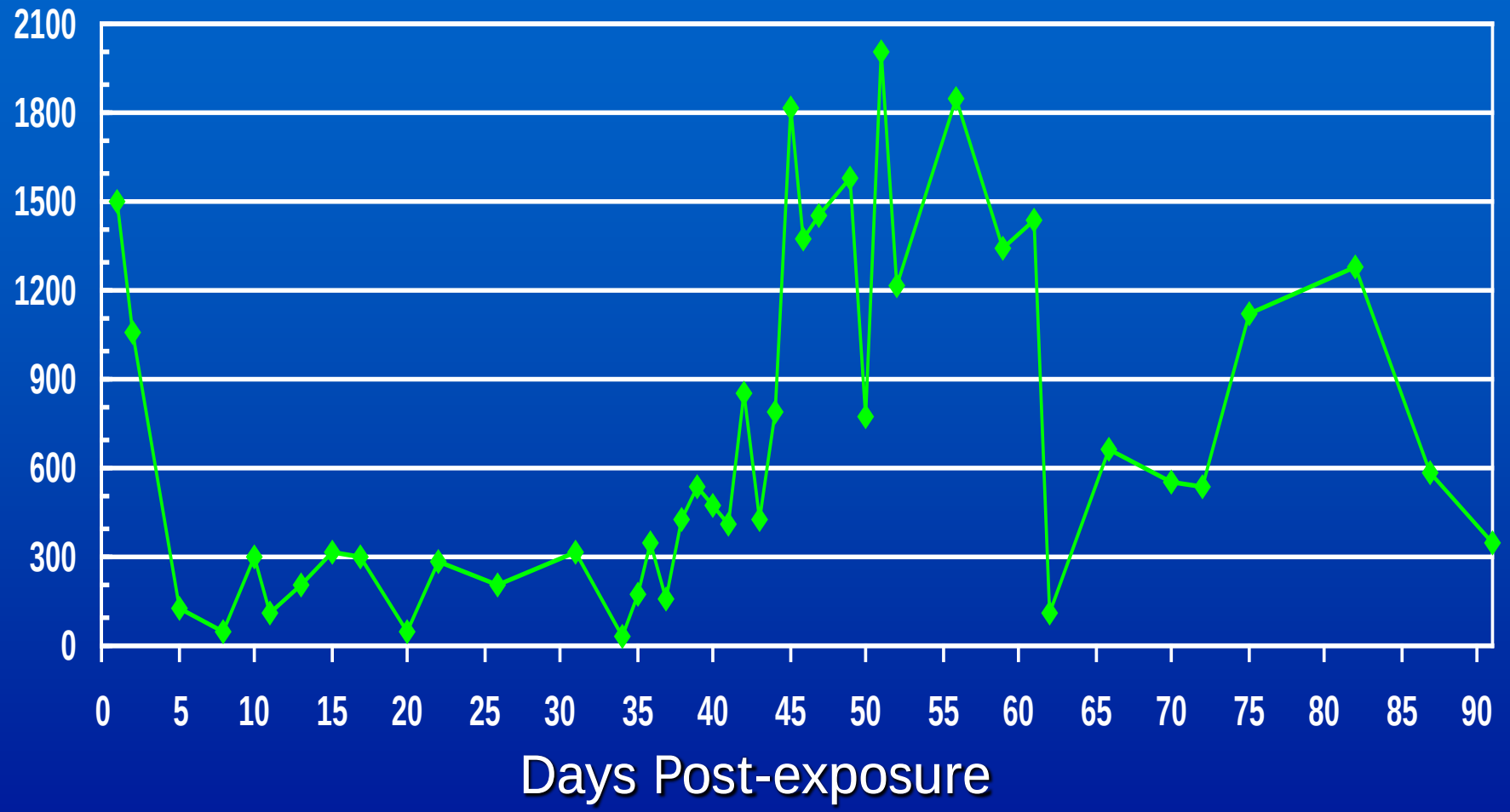

D+10 1 March 1999 Extended superficial erosion

D+15 6 March 1999 Genital herpes eruption. Zinnet 500mg t
& Acyclovir tid. Cipro stopped.

D+24 15 March 1999 - Hyperpigmentation.

^{40}C/O numbness lateral right thigh with hypersensitivity on medial aspect.

D+28 19 March 1999 - IAEA experts arrive and jointly review case with Peruvian doctors

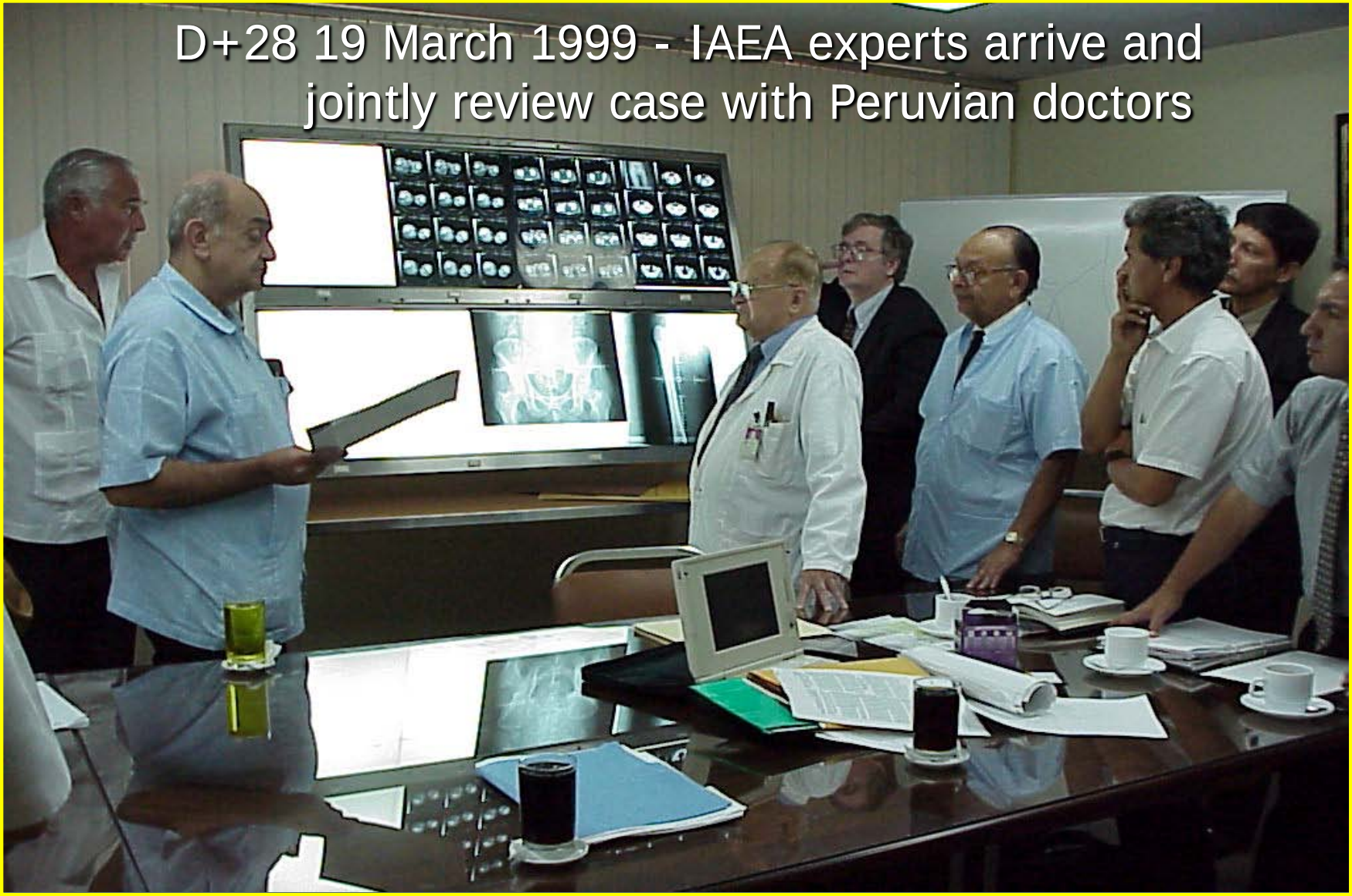

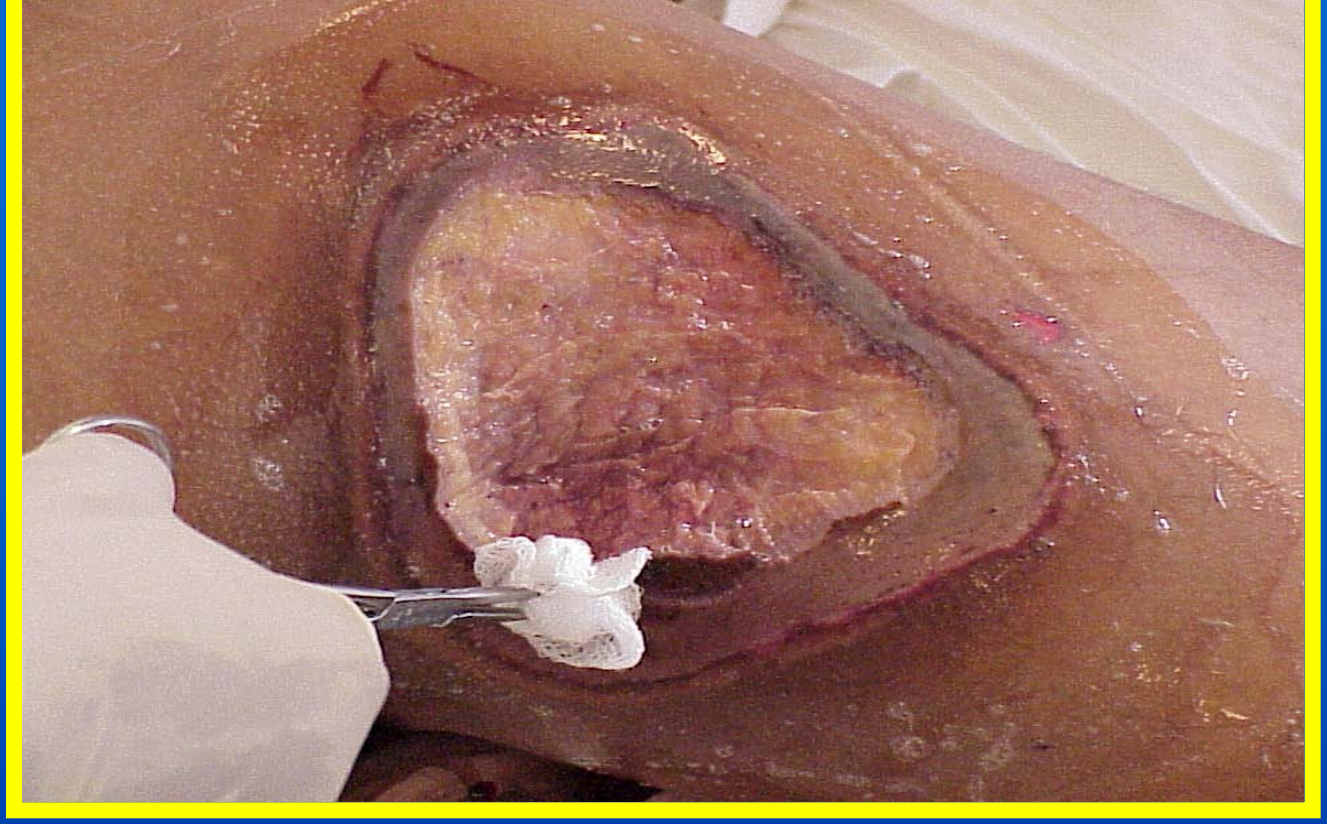

D+28 19 March 1999 Ulcerative lesion 2cm deep - continues to expand.

D+32 Increasingly painful. Morphine infusion started. Radiation-induced sciatic neuropathy.

D+39 First febrile episode.

Late March - More resource intensive. Nursing care and medical procedures very time consuming. Lesions now appearing on right hand.

April 1999

- Multiple Infections (*Klebsiella*, *Staph aureus*, *Enterobacter*, *E. coli,* and others) and sepsis
- Multiple antibiotic regimes administered
- Gastric ulcer
- Multiple whole blood transfusions
- Surgical debridement reveals extensive area of necrosis

May 1999

- Continued tissue destruction complicated by recurrent infections, anemia and pain
- Hyperbaric oxygen treatments 1 hour qd x 20 days with minimal success
- Electromyography reveals no functional muscle innervation from the perineal and posterior tibia nerves
- Transfer to Percy Military Hospital in Paris for artificial skin graft

Treatment in France

- MRI confirmed massive radionecrosis of right femur and surrounding tissue
- Persistent bacterial infection with multi-resistant germs complicate skin grafts
- Late July 1999 - repeated skin graft attempts had failed to achieve granulation
- 16 August 1000 - disarticulation of hip followed by a left iliac colostomy
- 19 September 1999 (day 205) - transfer to a rehabilitation center
- Radionecrosis extends into the perineum with the anal sphincter and basal part of the scrotum requiring resection

Return from France to Peru 17 October 1999

- Very depressed with chronic pain
- Ulcerated perineum continues to extend
- Transferred back to ICU in his hometown

Ischial bone exposed. Urethral necrosis.

Continued Complications in the Healing Process

14 December 1999
Necrotic lesions lateral left leg

28 April 2000
Recurrent ulceration & vasculitis lateral left leg

Others Potentially Affected

- Workers at site
- 15 passengers on the mini-bus with the welder as he went home
- Immediate family at the residence
  - o wife and 3 children ages 10, 7, and 18 months - no hematological changes observed in wife or children though wife did develop skin lesion

Moist desquamation on wife's sacral region 18 March 1999

October 2001

October 2001

LRI Issues

- There can be uncertainties associated with physical dose estimates and observed biological effects
- With evidence of BM suppression, cytokines should be given as soon as possible
- While difficult to determine, earlier surgical intervention may have prevented involvement of tissues into the peri-anal region
- Psychosocial well being of the patient should be constantly addressed in the long-term healthcare plan

Questions